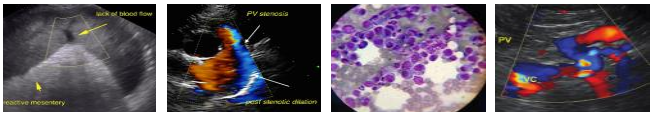

SonoPath.com
1-800-838-4268 info@sonopath.com

DATE

12/19/22

PERFORMED BY:

Rebekah Jakum

INTERPRETED BY

Keith Blass, DVM, MS, DACVIM (Cardiology)

PATIENT

Wyatt Wilson

SPECIES

Canine

BREED

Great Dane

SEX

MN

AGE

9 y

WEIGHT

118 lb

HOSPITAL NAME

Good Hope AH

REFERRING VET

Dr. Weekes

PRESENTING CLINICAL SIGNS

History: Diagnosed with DCM in April 2022. Receiving pimobendan 10 mg BID, taurine, carprofen, and cefpodoxime.

ECHOCARDIOGRAPHIC FINDINGS

2D, M-mode, and Doppler study.

Left atrial size is normal. The mitral valve appears normal, though mild mitral regurgitation is present. There is mild left ventricular dilation. There is very mild left ventricular systolic dysfunction. The aorta and aortic valve are normal. Right atrial and right ventricular dimensions are normal. The tricuspid valve is normal. The pulmonary artery and pulmonic valve are normal. No shunting lesions are visualized. No heartworms are visualized. No pericardial effusion or cardiac masses are seen.

LA – 48.6 mm
LVIDd – 55.1 mm
LVIDs – 41.9 mm
FS – 24%
LVOT – 1.76 m/s
RVOT – 1.28 m/s

ASSESSMENT/RECOMMENDATIONS

Dilated cardiomyopathy (DCM)

This examination demonstrates some improvement compared to Wyatt's previous echocardiogram, as he now has only very mild depression of his left ventricular systolic function and his left atrial size is normal. Given this improvement, Wyatt's current risk for the development of clinical signs secondary to his cardiac disease, such as coughing, exercise intolerance, syncope, labored breathing, and abdominal distension, appears to be fairly low, though careful monitoring for these signs is still recommended.

No change therapy is recommended based on this exam.

A recheck echocardiogram is recommended in ~6 months, sooner if new clinical signs compatible with cardiac dysfunction develop.

The information and recommendations provided are based on the images presented by the referring veterinarian. No evaluation can be communicated regarding pathology that was not visible in the image/video clips provided.

Thank you for this referral. If the clinical or image interpretation does not parallel your findings or

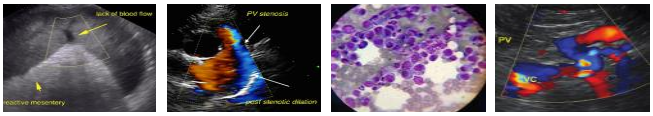

if I can be of any further assistance please contact me.

Keith Blass, DVM, MS, DACVIM (Cardiology)
KeithBlass@gmail.com
631-804-5754

DATE

12/19/22

PERFORMED BY:

Rebekah Jakum

INTERPRETED BY

Keith Blass, DVM, MS, DACVIM (Cardiology)

PATIENT

Wyatt Wilson

SPECIES

Canine

BREED

Great Dane

SEX

MN

AGE

9 y

WEIGHT

118 lb

HOSPITAL NAME

Good Hope AH

REFERRING VET

Dr. Weekes